

# Esthetic Printed Rim with Anterior Deprogrammer for Implant-Supported Full-Arch Rehabilitations: A Case Report

Germán Albertini, DDS

Diego Bechelli, DDS

Private practice, Buenos Aires, Argentina.

Aníbal Capusotto, DDS, PhD

Department of Integral Dentistry, Universidad de Buenos Aires, Buenos Aires, Argentina; Private practice, Buenos Aires, Argentina.

**Purpose:** To describe a digitally designed device for improving esthetic and occlusal planning for full-arch implant-supported rehabilitations. **Materials and Methods:** A step-by-step clinical and technical protocol is described to obtain an esthetic rim. Alternatives in terms of design and case requirements and the clinical use of the device are also described. **Results/Conclusion:** An integral approach based on esthetic and functional needs is mandatory in full-arch restorations. The proposed device can improve teamwork and communication, minimizing possible errors. Future proposals are needed to achieve a fully digital protocol in the fabrication of these rehabilitations. *Int J Prosthodont* 2021;34:829–837. doi: 10.11607/ijp.7456

The fabrication of an implant-supported prosthesis for edentulous patients involves a series of steps that should be meticulously performed. These organized stages are important in order to achieve a result that meets esthetic and occlusal expectations and assures clinical stability over time.

A fundamental step in the early stages of treatment is to share the clinical data with the dental technician, who will elaborate the prostheses. For this reason, the use of photographs, rims, or provisional prostheses to identify and set the esthetic parameters, skeletal referential planes, intermaxillary relationship, and other fundamental information is essential.<sup>1,2</sup> Nowadays, data collection can be done by analog or digital means.

Although many different techniques have been proposed, rims for implant-supported prostheses are still being elaborated following the universally accepted parameters used in mucosa-supported total prostheses based on average measurements that will later be confirmed or modified by the clinician.<sup>3,4</sup> The possibility of screwing the rims to the implants offers greater stability and precision<sup>5,6</sup>; however, factors such as a subgingival connection, divergent implants, and imprecise transference can make this process challenging, resulting in a difficult clinical step for the professional and an uncomfortable experience for the patient. Moreover, there is some complexity in recording a precise intermaxillary relation, because deprogramming attachments like the single central screw or other similar devices are usually left aside, which affects the precision in this crucial clinical step.<sup>7–12</sup>

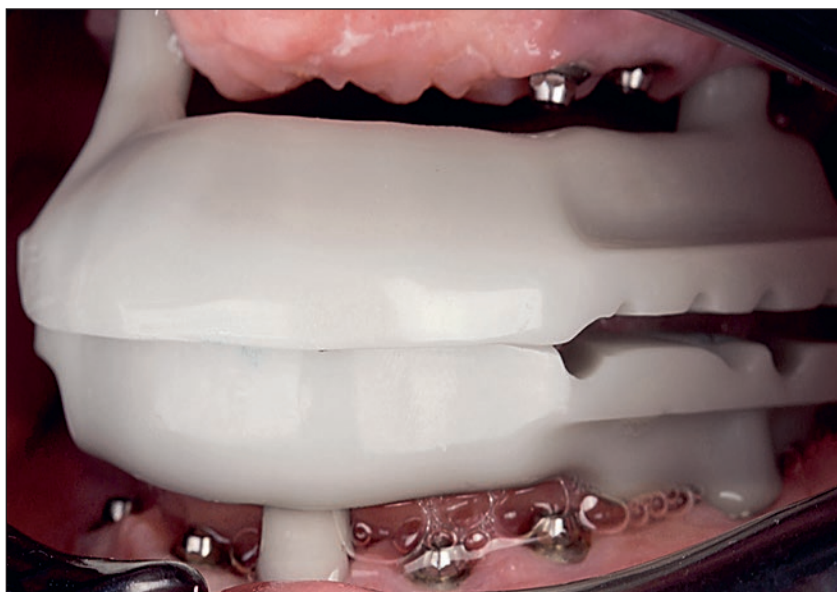
Digital technology allows the clinician to improve certain protocols and techniques due to the integration between meshes and different digital files. This is a useful process for obtaining the desired esthetic and occlusal integration. Using intraoral scans of the patient's current prostheses, facial scans, and clinical pictures to design customized rims can make these steps and techniques more friendly and precise.<sup>13,14</sup> The designs of these devices can include creative features, such as tooth shapes, planes, etc, for taking better intermaxillary records with anterior deprogrammers easily and accessibly for the clinician.<sup>15–18</sup>

**Correspondence to:**

Dr Diego Bechelli  
Avenida Gaona 1770 1A (1416)  
CABA, Buenos Aires, Argentina  
Email: db@clinicabechelli.com.ar

Submitted October 28, 2020;  
accepted July 20, 2021.

©2021 by Quintessence  
Publishing Co Inc.



**Fig 1** Maxillary and mandibular printed rims with anterior deprogrammer.

From a clinical point of view, an ideal planning device should have a customized design based on the patient's esthetic and functional references<sup>19,20</sup>; adequate stability, retention, and support; fluent clinical steps with fewer placing/pull-out repeats; and easy and comfortable obtainment of the vertical dimension of occlusion (VDO)<sup>21-23</sup> and centric relation of occlusion (CRO).<sup>24,25</sup>

The use of scan bodies and intraoral scanners (IOS) for full-arch rehabilitations has a background of low scientific support regarding the accuracy of current hardware.<sup>26</sup> Some specific hardware showed promising results,<sup>27</sup> but future research is needed to achieve strong supporting evidence. Photogrammetry technologies were proposed to solve this problem with promising results.<sup>28-31</sup> However, the classic open-tray impression with splinted transfer is still the best-supported option for full-arch structures, connecting several implants with a single-piece prosthesis.<sup>32-34</sup>

The design and protocol of a screwed esthetic printed rim with anterior deprogrammer (APRAD) for implant-supported full-arch rehabilitation is presented, with the aim of improving patient comfort and optimizing clinician chairside work time. Several options in terms of design and shape are given, according to different clinical cases and situations.

## MATERIALS AND METHODS

The designed device is based on a patient's current prosthesis (Fig 1). If such prostheses are not ideal in terms of esthetic or occlusal conditions, it is recommended to

undergo clinical improvement or minor digital reconstruction using pictures and meshes in an appropriate software (Smile Creator, Exocad). If the esthetic/occlusal requirements are not currently being met, major modifications are needed to achieve them.

Taking into account that there is not strong evidence available to support a fully digital protocol for full-arch rehabilitation, an analog transfer is still the safest way to obtain an accurate 3D implant position model. A step-by-step guide is proposed:

1. Facial photographs and an intraoral scan (Trios 3, 3Shape) of the prostheses and the surrounding mucosa, including the palate, are taken. This information will guide the technician when establishing the shape and volume of the future rim.
2. An analog impression using splinted implant transfers, polyvinyl siloxane (PVS), and the customized open-tray technique is performed.

The collected data are then sent to the lab to perform the following steps:

1. Fabrication of a master cast model, obtained from the conventional impression.
2. Bench scanning of cast model (Ceramill Map, Amann Girrbach) with the scan bodies screwed onto the implant replicas; the file is then uploaded to the design software (Exocad)
3. Superimposition of files on design software (intraoral scan and bench scan files; Fig 2a)

Once the software superimposes the working model and the patient's previous prostheses, the implants for screw retention are selected, and the shape and size of the rims are designed (Figs 2b and 2c).

From a design point of view, the rim has three zones: the esthetic, the functional, and the deprogramming zones (Fig 3).


There are several design possibilities in the esthetic zone, such as printing the rim smooth or with an anatomical shape on the anterior sector as a guide to visualize the esthetic aspects and dentolabial dynamics (Fig 4). The maxillary anterior palatal sector of the rim is designed with a similar shape to an occlusal splint.

In the functional zone, the device should be 2 to 3 mm below the occlusal plane of the referential prostheses, which avoids occlusal contact during the self-induced record. The occlusal surface must have grooves to be captured by the IOS. The width of this area should be 1 to 2 mm greater than the occlusal platform of the prostheses. The lack of occlusal contact between the rim and the opposite arch is a necessary principle for future deprogramming.

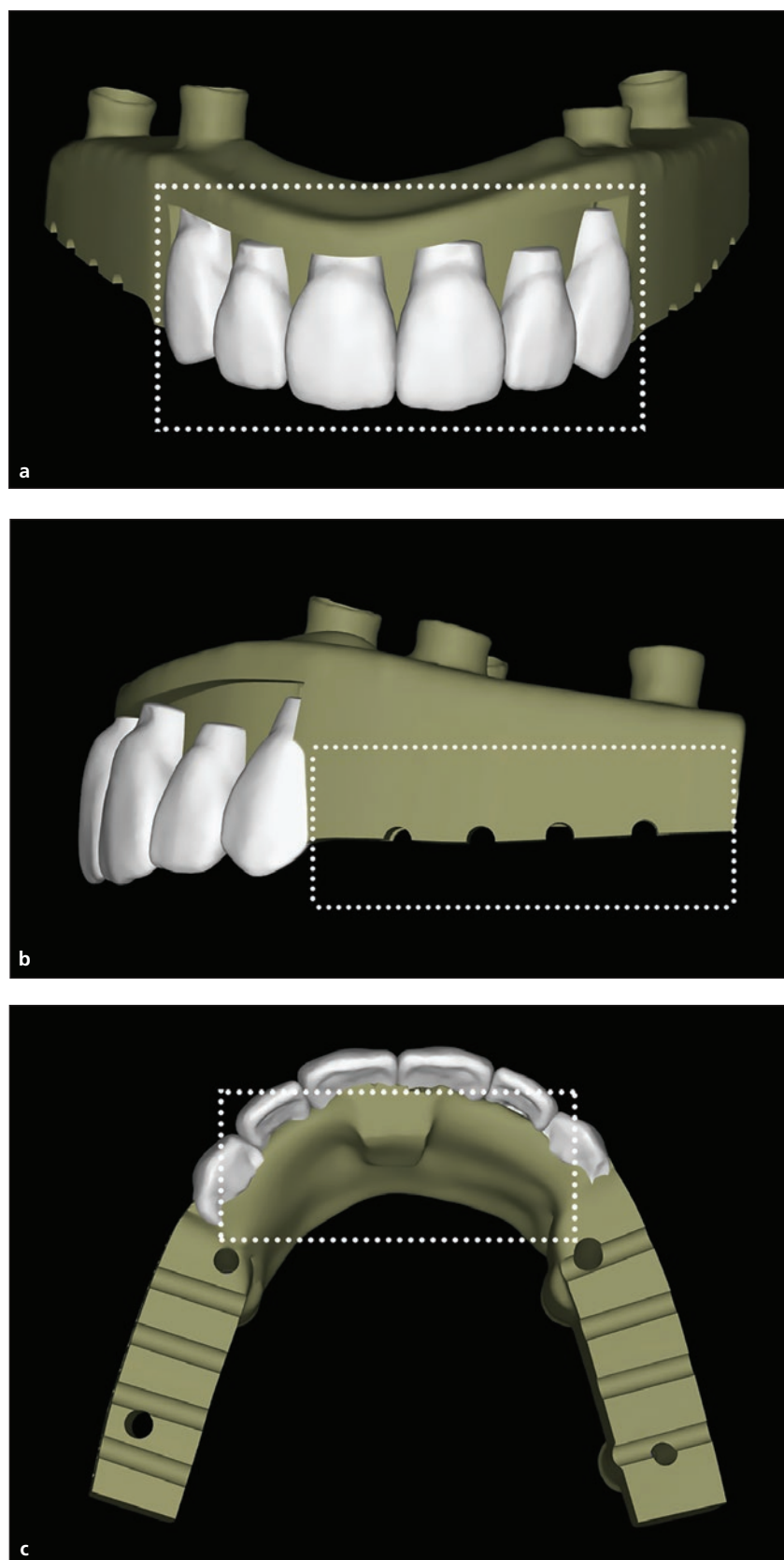
The design of the deprogramming zone (palatal face) will depend on which kind of deprogrammer is chosen. It could be smooth and with an inclination like a Lucia Jig, to be articulated with an incisal pin on the opposite arch for Gothic arch tracing; it may have bilateral canine contact; or it may have a palatal bite plane without inclination, like a Kois deprogrammer (Fig 5).

Regarding the mandibular rim, the anatomy of the anterior sector must be similar to the referential prostheses (Fig 6), with a little acute mound on the midline to allow for an intermaxillary record through Gothic arch tracing on the palatal side of the maxillary rim.

In the case of a single maxillary prosthesis, a printed jig with the shape of an inscription spike to place



**Fig 2** Maxilla rim design. (a) Overlapped meshes to determine the size and shape of the anterior deprogrammer. (b) Design of the rim based on current prostheses. (c) Abutment selection and final design, ready for 3D printing.



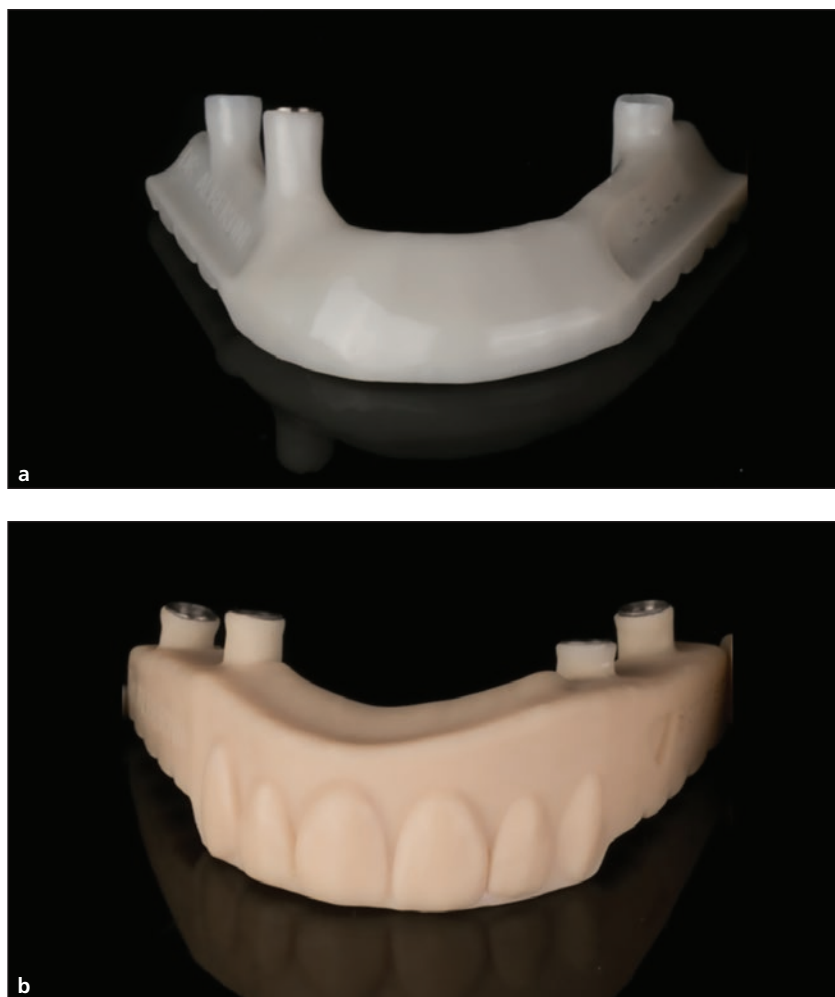
**Fig 3** The (a) esthetic, (b) functional, and (c) deprogramming zones.

on the anterior teeth can be made. For single mandibular prosthesis cases, a device similar to a Lucia jig on the maxillary anterior teeth is recommended.

The designed device is printed (Max UV, Asiga). Once the rim is screwed in the patient's mouth, the following clinical steps are proposed to obtain the esthetic and occlusal information:

1. Upper lip support: The rim's angulation will be verified through a facial visualization with the lips in closed/resting position by frontal and lateral analysis. The buccal volume of the APRAD can be reduced or augmented as preferred, according to the analysis results.
2. Maxillary incisal edge (UIE): The length of the maxillary central incisors will be determined by the rim exposure when the upper lip is in the resting position and after some phonetic testing. The rim can be originally designed with some millimeters of incisal oversize to allow for adjustment directly inside the patient's mouth (Fig 7).
3. Maxillary middle dental line: Based on facial and dentolabial parameters.
4. Smile line: Analysis of the gingival margin of the maxillary anterior teeth is based on the position of the lips when the patient is smiling.
5. Maxillary occlusal plane: Determined with the frontal (horizontal bipupillary plane) and lateral (Camper's plane) views based on the photographs, the superimposed files, and the virtual articulator.
6. VDO: With a mandibular closing rim, the lower spike is adjusted over the maxillary rim. Then, the facial and dentolabial aspects from the frontal and lateral views are evaluated (Fig 8).
7. Setting a CRO: Using articulating paper in the anterior area of the

**Fig 4** Different design options for printed rims. (a) Smooth buccal rim with anterior deprogrammer. (b) Esthetic rim with anterior deprogrammer, including dental shapes.



rims, centric and eccentric mandibular movements (protrusive and lateral movements) are indicated to the patient. The CRO must be identified at the vertex of the arrow (Fig 9a) or in the simultaneous bilateral canine contacts (Fig 9b), depending on which method was chosen.

8. Registering the CRO: With the patient in CRO, an intraoral scanning of the posterior lateral surfaces is done, and the position is recorded (Fig 10).

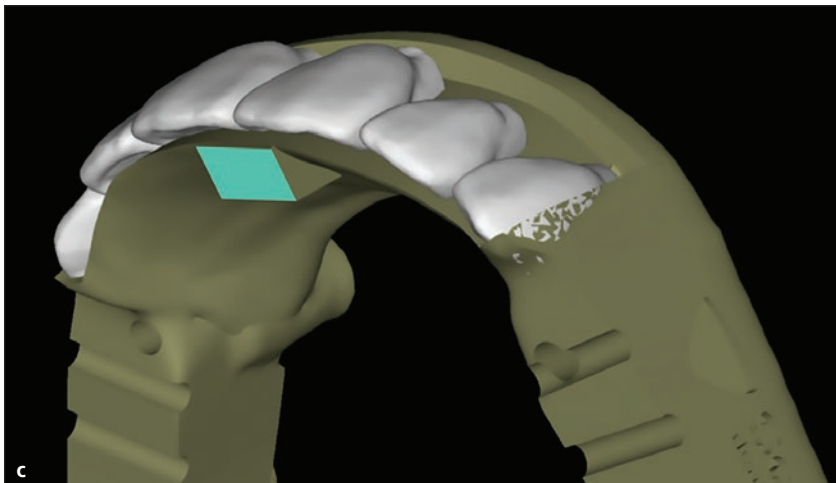
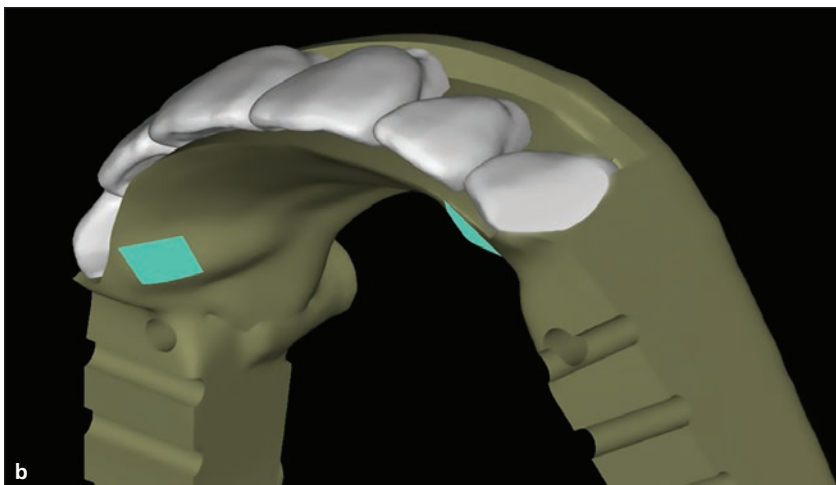
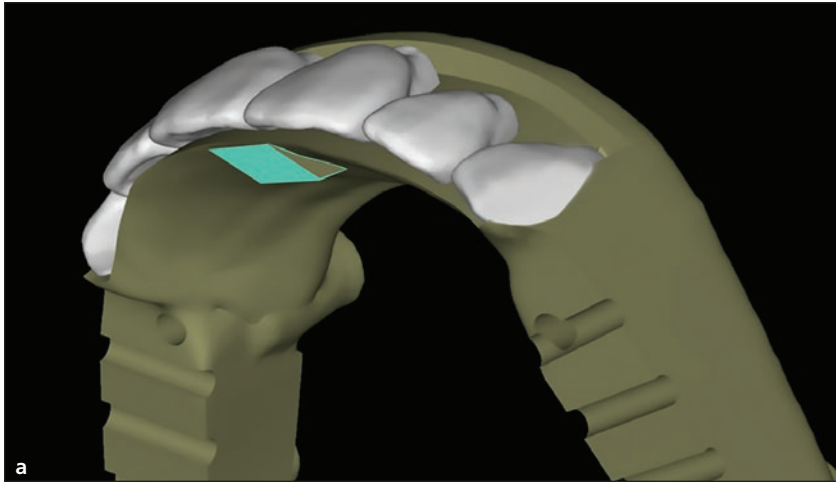
## DISCUSSION

The intermaxillary relationship in full-arch implant restorations has always been a challenge for the clinician and has great importance for the lab technician's work.

Digital technologies offer advantages regarding the development of personalized devices that allow for some reduction in clinical/laboratory working time, optimizing

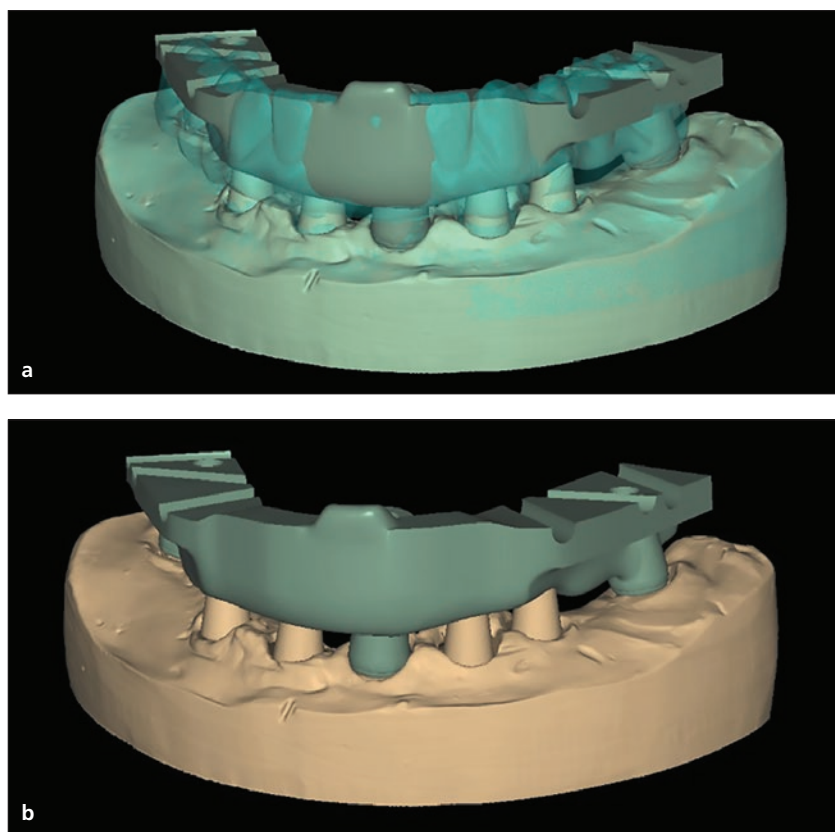
the required steps to achieve a suitable implant-supported prosthesis. The learning curve to achieve an optimal use of some of these tools can be difficult, and, moreover, constant updates and new features arrive faster than scientific evidence. Thus, clinicians should focus mainly on procedure objectives rather than on the digital tools used to perform it.

The proposed protocol combines classical impressions and digital techniques to utilize the best features of each. The improvement of esthetic communication, taking advantage of provisional prosthesis information, and the possibility of a self-induced workflow for occlusal data result in a superior clinical process, reducing time-consuming sessions. However, an analog step is still necessary to obtain an accurate working model, and some skills in digital design tools and 3D printers are also needed. Further research is required to provide stronger evidence of the effectiveness and feasibility of this device and to obtain a safe fully digital protocol for edentulous patients.

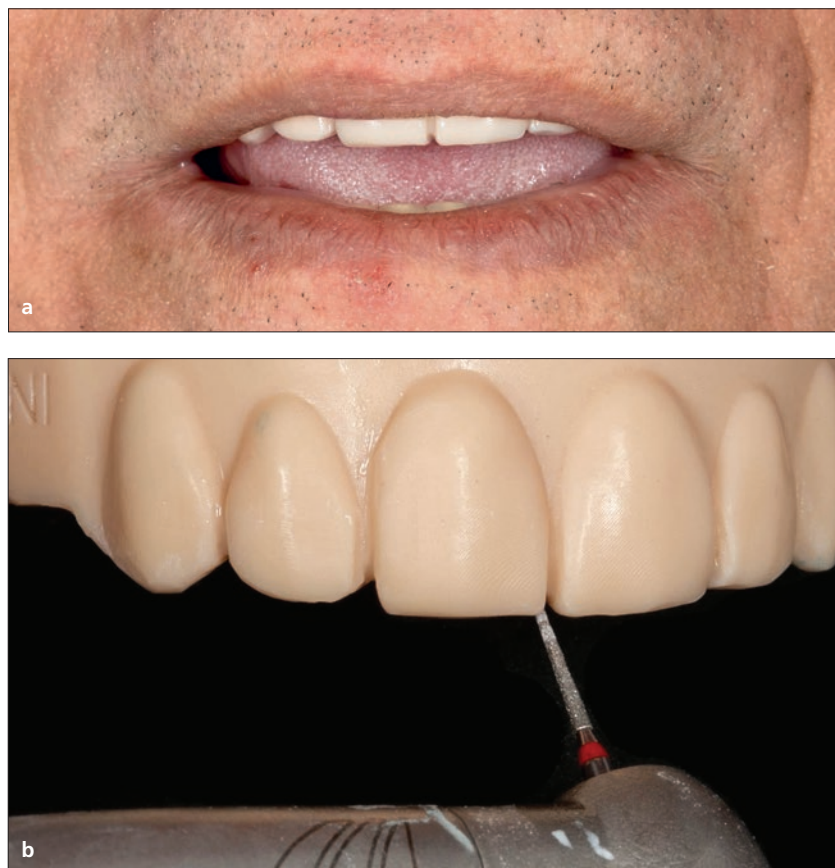


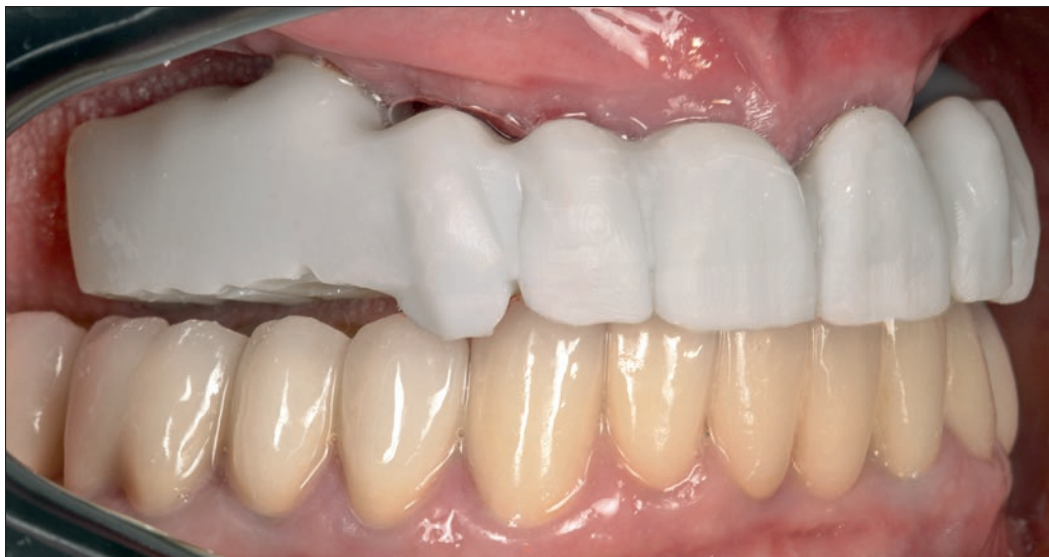**Fig 5** Deprogramming options in the anterior zone. (a) Tilted plane (Lucia jig-style). (b) Canine stops for simultaneous and bilateral canine contact. (c) Horizontal plane (Kois-style).

**Fig 6** Mandibular rim design. (a) Initial rim design based on the current prosthesis. (b) Final mandibular rim design with anterior incisal mound for deprogramming and selected abutments.

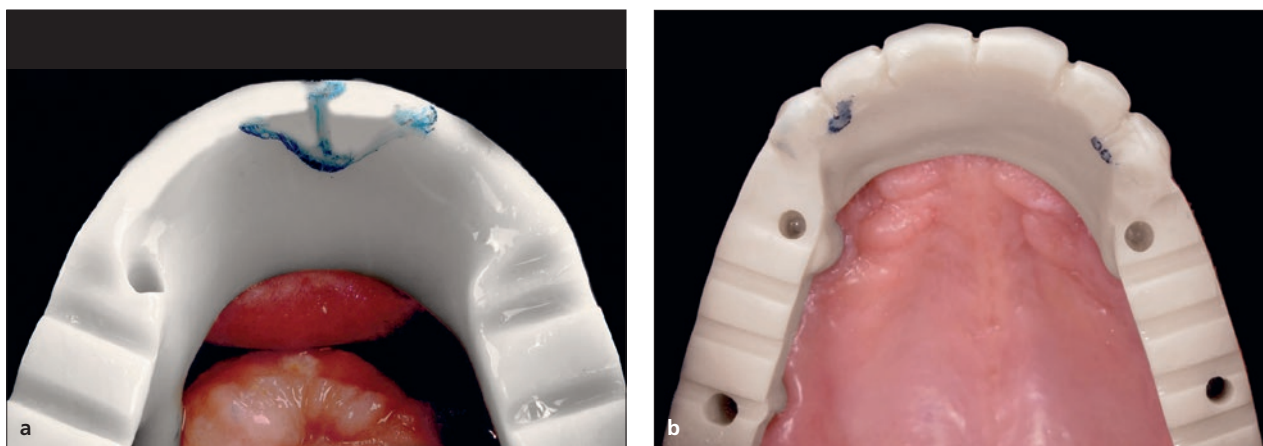


**Fig 7** Esthetic parameters. (a) Determination of maxillary incisal edge based on the patient's lips at rest. (b) The customizable esthetic printed rim can be adjusted as preferred.

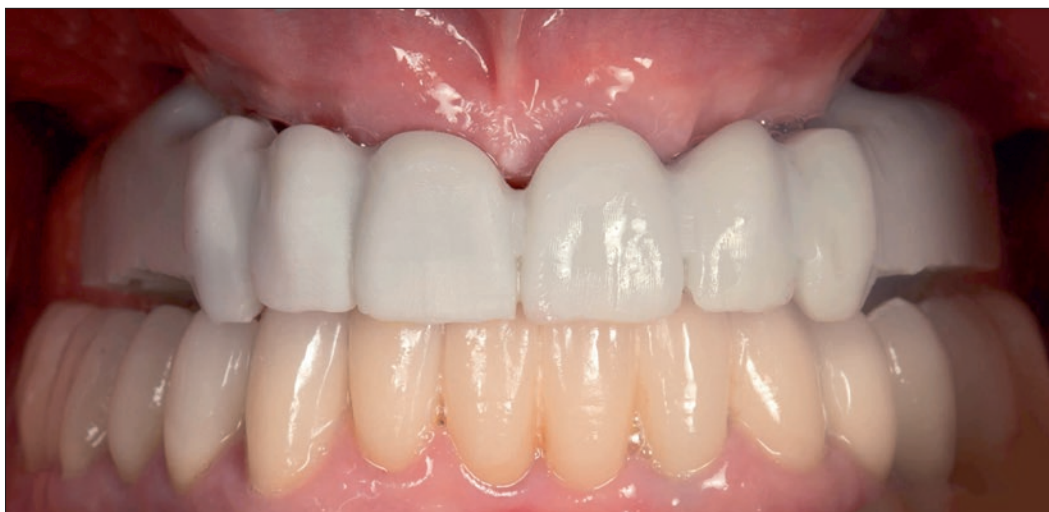



**Fig 8** Maxillary rim in place, establishing a new vertical dimension of occlusion.



**Fig 9** CRO position. (a) Gothic arch recording. (b) Simultaneous and bilateral canine contact.



**Fig 10** The final centric relation of occlusion and vertical dimension of occlusion positions are scanned intraorally.



## CONCLUSIONS

From this publication, the following conclusions could be reached:

1. The esthetic printed rim with anterior deprogrammer may improve teamwork communication by the collection of esthetic and functional references, in an easier, faster, and more precise way, minimizing possible mistakes.
2. With the esthetic printed rim with APRAD, it is possible to capture CRO and the selected VDO at the same time with a single digital record.

## ACKNOWLEDGMENTS

The authors would like to acknowledge MDTs Nestor Lui, Juan Andrés Tellaeche, Ricardo Schäfer, and Pablo Schäfer for their invaluable work and also Dr Andres E. Curra for his collaboration. The authors report no conflicts of interest.

## REFERENCES

1. Sharry JJ. Complete Denture Prosthodontics, ed 2. New York: McGraw-Hill, 1968.
2. Sadowsky SJ. The role of complete denture principles in implant prosthodontics. *J Calif Dent Assoc* 2003;31:905–909.
3. Rungcharassaeng K, Kan JY. Fabricating a stable record base for completely edentulous patients treated with osseointegrated implants using healing abutments. *J Prosthet Dent* 1999;81:224–227.
4. Misch CE. *Dental Implant Prosthetics*. St Louis, MO: Mosby 2005:245–247.
5. Hobo S, Ichida E, Garcia LT. Osseointegration and Occlusal Rehabilitation. Chicago, IL: Quintessence; 1989:159–162, 171–173.
6. Loos LG. A fixed prosthodontic technique for mandibular osseointegrated titanium implants. *J Prosthet Dent* 1986;55:232–242.
7. Meyer FS. A new, simple and accurate technic for obtaining balanced and functional occlusion. *J Am Dent Assoc* 1934;21:195–203.
8. Savabi O, Nejatidanesh F. Interocclusal record for fixed implant-supported prosthesis. *J Prosthet Dent* 2004;92:602–603.
9. Massad JJ, Connelly ME, Rudd KD, Cagna DR. Occlusal device for diagnostic evaluation of maxillomandibular relationships in edentulous patients: A clinical technique. *J Prosthet Dent* 2004;91:586–590.
10. Kokubo Y, Ohkubo C. Occlusion recording device for dental implant-supported restorations. *J Prosthet Dent* 2006;95:262–263.
11. Kindrknecht KE, Wong GK, Billy EJ, Li SH. The effect of anterior deprogrammer on the position of the terminal transverse horizontal axis of the mandible. *J Prosthet Dent* 1992;68:123–131.
12. Hunter BD 2nd, Toth RW. Centric relation registration using an anterior deprogrammer in dentate patients. *J Prosthodont* 1999;8:59–61.
13. Lanis A, Alvarez del Canto O, Barriga P, Polido WD, Morton D. Computer-guided implant surgery and full-arch immediate loading with prefabricated-metal framework-provisional prosthesis created from a 3D printed model. *J Esthet Restor Dent* 2019;31:199–208.
14. Liu S, Srinivasan M, Mörzinger R, et al. Reliability of a three-dimensional facial camera for dental and medical applications: A pilot study. *J Prosthet Dent* 2019;122:282–287.
15. Carrol WJ, Woelfel JB, Huffman RW. Simple application of anterior jig or leaf gauge in routine clinical practice. *J Prosthet Dent* 1988;5:611–617.
16. Schuyler CH. An evaluation of incisal guidance and its influence in restorative dentistry. *J Prosthet Dent* 1959;9:374–378.
17. Lee R. Anterior guidance. In: Lundeen HC, Gibbs CH (eds). *Advances in Occlusion*. Postgraduate Dental Handbook, vol 14. Boston: John Wright, 1982:51–79.
18. Kois JC, Filder BC. Anterior wear: Orthodontic and restorative management. *Compen Contin Educ Dent* 2009;30:420–429.
19. Vig RG, Brundo GC. The kinetics of anterior tooth display. *J Prosthet Dent* 1978;39:502–504.
20. Niswonger ME. The rest position of the mandible and centric relation. *J Am Dent Assoc* 1934;21:1572–1582.
21. Silverman MM. Accurate measurement of vertical dimension by phonetics and the speaking centric space. Part I. *Dent Dig* 1951;57:261–265.
22. Pleasure MA. Correct vertical dimension and freeway space. *J Am Dent Assoc* 1951;43:160–163.
23. McGee GF. Use of facial measurements in determining vertical dimension. *J Am Dent Assoc* 1947;35:342–350.
24. Wojdyla SM, Wiederhold DM. Using intraoral Gothic arch tracing to balance full dentures and determine centric relation and occlusal vertical dimension. *Dent Today* 2005;24:74–77.
25. Rubel B, Hill EE. Intraoral gothic arch tracing. *NY State Dent J* 2011;77:40–43.
26. Wismeijer D, Joda T, Flügge T, et al. Group 5 ITI Consensus Report: Digital technologies. *Clin Oral Implants Res* 2018;29(suppl 16):s436–s442.
27. Amin S, Weber HP, Finkelman M, El Rafie K, Kudara Y, Pappaspyridakos P. Digital vs conventional full-arch implant impressions: A comparative study. *Clin Oral Implants Res* 2017;28:1360–1367.
28. Agustín-Panadero R, Peñarrocha-Oltra D, Gomar-Vercher S, Peñarrocha-Diago M. Stereophotogrammetry for recording the position of multiple implants: Technical description. *Int J Prosthodont* 2015;28:631–636.
29. Sánchez-Monescillo A, Sánchez-Turrión A, Vellon-Domarco E, Salinas-Goodier C, Prados-Frutos JC. Photogrammetry impression technique: A case history report. *Int J Prosthodont* 2016;29:71–73.
30. Peñarrocha-Oltra D, Agustín-Panadero R, Pradies G, Gomar-Vercher S, Peñarrocha-Diago M. Maxillary full-arch immediately loaded implant-supported fixed prosthesis designed and produced by photogrammetry and digital printing: A clinical report. *J Prosthodont* 2017;26:75–81.
31. Ortorp A, Jemt T, Bäck T. Photogrammetry and conventional impressions for recording implant positions: A comparative laboratory study. *Clin Implant Dent Relat Res* 2005;7:43–50.
32. Pradies G, Ferreiroa A, Özcan M, Giménez B, Martínez-Rus F. Using stereophotogrammetric technology for obtaining intraoral digital impressions of implants. *J Am Dent Assoc* 2014;145:338–344.
33. Pappaspyridakos P, Chen CJ, Gallucci GO, Doukoudakis A, Weber HP, Chronopoulos V. Accuracy of implant impressions for partially and completely edentulous patients: A systematic review. *Int J Oral Maxillofac Implants* 2014;29:836–845.
34. Joda T, Ferrari M, Gallucci GO, Wittneben JG, Brägger U. Digital technology in fixed implant prosthodontics. *Periodontol* 2000 2017;73:178–192.